


ISSN (E): 2708-2601

ISSN (P): 2708-2598

Medical Journal of South Punjab

Article DOI: 10.61581/MJSP.VOL04/01/04

Volume 4, Issue 1, 2023



Comparison of the Outcome of 0.02% Mitomycin C versus Limbal Conjunctival Autograft after Primary Pterygium Excision

Publication History

Received: March 30, 2023 Revised: April 10, 2023

Published: June 03, 2023 Accepted: May 21, 2023

An official publication of

Medteach Private Limited, Multan, Pakistan.

Email: farman@mjsp.com.pk, Website: <https://mjsp.com.pk/index.php/mjsp>

Authors and Affiliation:

Syed Nishat Akram^{1*}, Muhammad Ajmal Chaudhary², Muhammad Ajmal³, Nesr Farooq⁴,

^{1,4}Shalamar Medical & Dental College Hospital, Lahore, Pakistan

²Sheikh Zayed Medical College & Hospital, Rahim Yar Khan

³Children's Hospital, Lahore, Pakistan

*Correspondence Email:

nishatbukhari@gmail.com

Copyright & Licensing:



Authors retain copyright and grant the journal right of first publication with the work simultaneously licensed under a [Creative Commons Attribution \(CC-BY\) 4.0 License](https://creativecommons.org/licenses/by/4.0/) that allows others to share the work with an acknowledgment of the work's authorship and initial publication in this journal.

Conflict of Interest:

Author(s) declared no conflict of interest.

Acknowledgment:

No Funding received.

Citation: Akram SN, Chaudhary MA, Ajmal M, Farooq N. Comparison of the outcome of 0.02% mitomycin C versus limbal conjunctival autograft after primary pterygium excision. Medical Journal of South Punjab. 2023 June 3; 4(1):36-43.

Please scan me to access online.





Comparison of the outcome of 0.02% mitomycin C versus limbal conjunctival autograft after primary pterygium excision

Syed Nishat Akram^{1*}, Muhammad Ajmal Chaudhary², Muhammad Ajmal³, Nesr Farooq⁴,

^{1,4}Shalamar Medical & Dental College Hospital, Lahore, Pakistan

²Sheikh Zayed Medical College & Hospital, Rahim Yar Khan

³Children's Hospital, Lahore, Pakistan

*Corresponding Author Email: nishatbukhari@gmail.com

ABSTRACT

Objective: The present study aimed to compare the outcomes of mitomycin 0.02% intra-operatively and limbal conjunctival autograft after excision of primary pterygium.

Methods: This randomized control trial was conducted at Shalamar medical and dental collage, Lahore, Pakistan. A total of 62 patients enrolled in study. Patients were divided into two groups MMC and LCAG. Main variables of study were laterality of pterygium, size of pterygium cross limbus, preoperative and post-operative BCVA and proportion of pterygium recurrence in both groups. SPSS version 24 was used for data analysis.

Results: Laterality were right for 48.4% patients in Group MMC and 58.1% for Group LCAG, ($p=0.445$). The average Size of pterygium cross limbus, Preoperative and postoperative BCVA of both the groups were almost equal, ($p>0.050$). The recurrences at 3, 6 & 9 months and after 1 year in Group MMC was 12.9%, 6.5%, 16.1%, 9.7%, 45.2% which is greater than Group LCAG 9.7%, 9.7%, 3.2%, 6.5%, 29% respectively, but the difference was statistically insignificant, ($p=0.526$).

Conclusion: Limbal conjunctival autograft is more successful in prevention of recurrence after excision of primary pterygium as compare intraoperative application of mitomycin-c. But simple excision and LCAG or MMC both are acceptable in terms of minor difference in recurrence rate, surgeon's skill and preferences of local practice are main risk factors.

Keywords: Limbal conjunctival autograft, Pterygium excision, Mitomycin-c 0.02%, Recurrence

1. INTRODUCTION

Pterygium is a condition observed worldwide with a pterygium belt between south of equator and 30° north latitude¹. Pterygium is an extension of connective tissues onto the cornea from bulbar conjunctiva or an overgrowth of triangular fibro-vascular cells². At its early stages it may be cosmetic blemish but in later stage can lead to astigmatism and impaired visual acuity, lacrimation, foreign body sensation and epithelial keratopathy³.

Among risk factors of pterygium, exposure to ultraviolet radiation is most common for its development⁴. Multiple techniques of its management are in practice, simple excision is old technique associated with high recurrence rate ranging 24% to 89%⁵. In recent researches addition of mitomycin C (MMC) with simple excision is reported as safe, effective and less association of recurrence. But, mitomycin C have some fatal complications like microbial infection and sclera necrosis⁶.

Another latest management option is conjunctival graft (CG) in which limbal epithelium acts as junctional barrier inhibit

overgrowth of conjunctiva⁷. As a result of this procedure local limbal deficiency considered as pterygium represent. Through addition of limbal epithelium in conjunctival graft barrier function of limbus can be restored⁸. In recent literature efficacy of limbal autograft transplantation in terms of reduction of recurrence of pterygium is reported, even number of studies were published on comparison of MMC and CG⁹. During comparison of MMC and CG results should be compared in terms of intraoperative/postoperative MMC, primary or recurrent pterygium LCAG or simple CG¹⁰. Previously published literature shows superiority of LCAG in reduction of pterygium recurrence over MMC and simple CG. Since the day of these latest techniques invention, no local study with prospective design was conducted to compare MMC and LCAG¹¹. So, this study with prospective randomized design was planned to assess effectiveness of these adjuvant.

2. METHODOLOGY

Study was carried out at ophthalmology department of Study was conducted at Ophthalmology department

Shalamar hospital, Lahore from October 2021 to September 2022 in duration of 1 year. Study was initiated after approval from hospital review board and taking informed consent from patients. Patients were informed about purpose of study and ensured about confidentiality of their data. Sample size was calculated by using WHO sample size calculator with confidence interval (CI) 95%, study power 80%, recurrence in mitomycin C group was 15.9% and 1.9% in LCAG group. Collection of sample was done by using non probability consecutive sampling. Patients presented for excision of primary pterygium were enrolled in study. Patients with autoimmune disease, collagen vascular disease, ocular surface pathology, pregnancy, double head pterygium and previous limbal surgery were excluded from study.

Recruited patients were randomized into two groups MMC and LCAG groups by lottery method. In MMC group patients received 0.02% MMC intra-operatively and limbal conjunctival autograft technique was used in LCAG group. Detailed examination of patients

was done for monitoring of intraocular pressure, visual acuity, biomicroscopy, extra ocular movements, and measurement of pterygium size and fundoscopy. Patients were followed up at 3, 6, 9 weeks and then at 1-year duration. After standard peribulbar anesthesia pterygium head was detached and body was dissected from overlying conjunctiva. Margins were cleared by excision of subconjunctival pterygial tissue and MMC 0.02% was applied for five minutes to bare sclera and site was irrigated with 150ml normal saline. Peripheral conjunctiva from pterygium was excised and edges were sutured 2 to 3 mm from limbus area.

Other technique includes pterygium excision and measurement of bare sclera, superior limbal region was used for harvesting of conjunctival graft (1 mm larger than recipient bed). Inferior margin of the graft was dissected towards the cornea. Safety of stroma was ensured in preventing possible pseudopterygium. Free graft was transferred for maintenance of polarity of tissue and secured with interrupted polyglactin (8.0). Postoperative medication (Pred

ford eye drops quarterly, ointment chloramphenicol TID) were advised for 1 month. At follow up examination fibro-vascular proliferation invading 1.5 mm of cornea labeled as recurrence.

Statistical analysis was performed on SPSS version 22.0, and frequency and percentages were calculated for categorical variables. Mean and standard deviation was used for presenting continuous variables.

3. RESULTS

Overall, 62 patients were included in our study. The study patients were equally divided into two groups; Group (MMC) and (LCAG). The average age of Group MMC and Group LCAG was 54.38 ± 3.78 years and 54.94 ± 2.85 years, respectively. There were more males than females in both the groups. Laterality were right for 15 (48.4%) patients in Group MMC and 18 (58.1%) for Group LCAG, ($p=0.445$).

The average Size of pterygium cross limbus, Preoperative and postoperative BCVA of both the groups were almost equal, ($p>0.050$). (Table. I).

The recurrences at 3, 6 & 9 months and after 1 year in Group

MMC was 12.9%, 6.5%, 16.1%, 9.7%, 45.2% which is greater than Group LCAG 9.7%, 9.7%, 3.2%, 6.5%, 29% respectively, but the difference was statistically insignificant, ($p=0.526$) (Table. II).

Table 1: Demographic and clinical characteristics among group

Variable	Group		p-value
	MMC n=32	LCAG n=32	
Age (years)	54.38± 3.78	54.94± 2.85	0.519
Sex			
Male	20 (64.5)	13 (41.9)	0.075
Female	11 (35.5)	18 (58.1)	
Laterality			
Right	15 (48.4)	18 (58.1)	0.445
Left	16 (54.6)	13 (41.9)	
Size of pterygium cross limbus (mm)	3.84±1 .16	4.09±1 .21	0.401
Preoperative BCVA	0.33±0 .11	0.30±0 .10	0.524
Postoperative BCVA after 1 year	0.22±0 .01	0.21±0 .21	0.674

Source: Author's Own Calculation

4. DISCUSSION

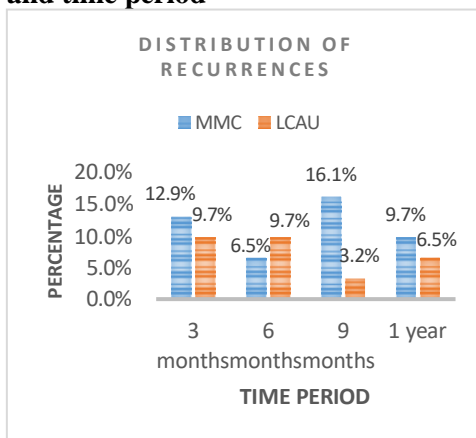
Mitomycin C is an antineoplastic agent that works by interrupting development of genetic material in a new cell¹². Main determinants of its efficacy include whether sclera is covered

with conjunctiva or not and stage at which MMC is used

Table-II: Distribution of recurrences among the groups

Period	Group		p-value
	MMC n=32	LCAG n=32	
3 months	4 (12.9)	3 (9.7)	0.526
6 months	2 (6.5)	3 (9.7)	
9 months	5 (16.1)	1 (3.2)	
1 year	3 (9.7)	2 (6.5)	
Total	14 (45.2)	9 (29.0)	

Fig-I: Distribution of recurrence and time period



Mitomycin C is an antineoplastic agent that works by interrupting development of genetic material in a new cell¹². Main determinants of its efficacy include whether sclera is covered with conjunctiva or not and stage

at which MMC is used. Its concentration of 0.02% is effective and use during surgery is preferred time. Alternate technique of MMC is conjunctival graft application¹³. The average age of Group MMC and Group LCAG was 54.38 ± 3.78 years and 54.94 ± 2.85 years, respectively. There were more males than females in both the groups. Recurrence was higher in MMC group 45.2% as compare to LCAG group 29%.

A similar study was conducted by Young et al¹⁴ on comparison of MMC 0.02% and LCAG in pterygium surgery, reporting mean age patients in MMC group 59.06 and in LCAG group 60.04 but majority of patients were female. In a study conducted by Chen et al¹⁵ and reported mean recurrence time 3.7-4.8 months and recurrence rate was noted in 6% cases and patients with recurrence are younger than those without recurrence. Increase in age is not associated with pterygium recurrence after controlling it's all types.

Ma et al¹⁶ conducted a study on comparison of MMC and CG in terms of recurrence rate and reported 5.4% recurrence rate

in conjunctival graft group and 3.5% in topical mitomycin C group, there was no statistically significant difference. Complication of infection was observed in a single patient in MMC group. In another by Sharma et al¹⁷, pterygium from twenty-one eyes was excised and mitomycin c and 20 were excised with conjunctival graft. Recurrence was observed in 14.3% and 5% of patients in mitomycin and CG groups respectively.

Manning et al¹⁸ conducted a study in 1997 and reported recurrence rate of pterygium 22.2% in conjunctival graft which is higher as compared to MMC group 21.1%. In this study it was also reported that intraoperative application of mitomycin is better to use than postoperative mitomycin-c. Another trial was conducted by Mutlu et al¹⁹ on comparison of mitomycin-c, conjunctival graft and limbal conjunctival autograft and reported no significant difference regarding recurrence rate of pterygia. Techniques used to harvest conjunctival graft and whole surgical procedure is also contributing factor.

Rao et al²⁰ completed a

study on Indian population, among 51 patients 17 were presented with recurrent pterygia and 36 were having primary pterygia. Recurrent pterygium was found in 3.2% of patients. It was concluded in this study that limbal grafting is essential in pterygium surgery. Jha et al²¹ also conducted a similar study on efficacy of limbal conjunctival autograft in primary and recurrent pterygium and reported that there was no recurrence and post-operative complication in 32 eyes. Peribulbar anesthesia techniques were used in this study similar to our study.

5. CONCLUSION

Limbal conjunctival autograft is more successful in prevention of recurrence after excision of primary pterygium as compare intraoperative application of mitomycin-c. But simple excision and LCAG or MMC both are acceptable in terms of minor difference in recurrence rate, surgeon's skill and preferences of local practice are main risk factors.

Limitations: Mostly patients belong to tribal areas of Punjab Pakistan, they are unaware of its

recurrence and complications, multiple attempts required to trace them for follow up that's why loss of follow up is main limitation of our study.

Recommendations: Further multi center studies with larger sample size are recommended.

REFERENCES

1. Kam KW, Young AL. Fifteen-year results of a randomized controlled trial comparing 0.02% mitomycin C, limbal conjunctival autograft, and combined mitomycin C with limbal conjunctival autograft in recurrent pterygium surgery. *Graefe's Arch Clin Experimental Ophthalmol*. 2019 Dec;257(12):2683-90.
2. Al-Salem KM, Saif AT, Saif PS. Comparing adjuvant beta radiation, mitomycin C, and conjunctival autograft in primary pterygium treatment, a three-year follow-up study. *The Open Ophthalmol J*. 2020 Dec 31;14(1):15-20.
3. Chan CM, Liu YP, Tan DT. Ocular surface changes in pterygium. *Cornea*. 2002 Jan;21(1):38-42.
4. Nassar MK, Khairy HA, Shalaby AM. Limbal conjunctival autograft versus simple excision with intraoperative mitomycin C in pterygium surgery. *Menoufia Med J*. 2018 Oct 1;31(4):1350.
5. Elshreef OK, Abdelwahab AM, Abu Elaish MH. Comparison between conjunctival autograft and intraoperative mitomycin C in surgical treatment of pterygium according to the recurrence rate. *J Recent Advances Med*. 2021 Jan 1;2(1):104-11.
6. Serri E, Saif MY, Ahmed A. Incidence of pterygium recurrence following bare sclera technique with MMC in comparison to conjunctival autograft. *J Ophthalmol Related Sci*. 2020 Sep 12;4(1):25-9.
7. Agahan AL, Merca TG, Tecson III JV, Panganiban MA. Recurrence and Complication Rates among Current Pterygium Treatment Techniques: Pre-operative Subpterygeal Mitomycin-C Injection, Intraoperative Mitomycin C Application and Pterygium Excision with

- Conjunctival Autograft. *Acta Medica Philippina*. 2020 Oct 28;54(5):530-35.
8. Humayun J, Farhan M, Kamran MK, Khan SA. Recurrence rate of primary pterygium following excision with mitomycin c versus excision with amniotic membrane transplant. *Paki J Ophthalmol*. 2020 May 4;36(3):12-15.
 9. Karukonda SR, Thompson HW, Beuerman RW. Cell cycle kinetics in pterygium at three latitudes. *Br Ophthalmol* 1995;79:313–17.
 10. Moran DJ, Hollows FC. Pterygium and ultraviolet radiation: a positive correlation. *Br J Ophthalmol*. 1984;68:343–6.
 11. Akinci A, Zilelioglu O. Comparison of limbal-conjunctival autograft and intraoperative 0.02% mitomycin-C for treatment of primary pterygium. *Intern Ophthalmol*. 2007 Oct;27(5):281-5.
 12. Lam DS, Wong AK, Fan DS. Intraoperative mitomycin C to prevent recurrence of pterygium after excision: a 30-month follow-up study. *Ophthalmol* 1998;105: 901–4.
 13. Dunn JP, Seamone CD, Ostler HB. Development of scleral ulceration and calcification after pterygium excision and mitomycin therapy. *Am J Ophthalmol* 1991;112:343–4.
 14. Young AL, Leung GY, Wong AK, Cheng LL, Lam DS. A randomised trial comparing 0.02% mitomycin C and limbal conjunctival autograft after excision of primary pterygium. *Br J Ophthalmol*. 2004 Aug;88(8):995-7. doi: 10.1136/bjo.2003.036830.
 15. Chen PP, Ariyasu RG, Kaza V. A randomized trial comparing mitomycin C and conjunctival autograft after excision of primary pterygium. *Am Ophthalmol*. 1995;120:151–60.
 16. Ma DH, See LC, Liao SB. Amniotic membrane graft for primary pterygium: comparison with conjunctival autograft and topical mitomycin C treatment. *Br J Ophthalmol* 2000;84:973–8.
 17. Sharma A, Gupta A, Ram

- J. Low-dose intraoperative mitomycin-C versus conjunctival autograft in primary pterygium surgery: long term follow-up. *Ophthalmic Surg Lasers* 2000;31:301–7.
18. Manning CA, Kloess PM, Diaz MD. Intraoperative mitomycin in primary pterygium excision. A prospective, randomized trial. *Ophthalmology* 1997;104:844–8.
19. Mutlu FM, Sobaci G, Tatar T. A comparative study of recurrent pterygium surgery: limbal conjunctival autograft transplantation versus mitomycin C with conjunctival flap. *Ophthalmology* 1999;106:817–21.
20. Rao SK, Lekha T, Mukesh BN. Conjunctival-limbal autografts for primary and recurrent pterygia: technique and results. *Indian J Ophthalmol* 1998;46:203–9.
21. Jha KN. Conjunctival-Limbal Autograft for Primary and Recurrent Pterygium. *Med J Armed Forces India*. 2008 Oct;64(4):337-9