


ISSN (E): 2708-2601

ISSN (P): 2708-2598

Medical Journal of South Punjab
Article DOI:10.61581/MJSP.VOL05/01/14
Volume 5, Issue 1, 2024



**Grommet insertion in patients of
secretory otitis media for improvement in
Hearing**

Publication History

Received: Mar, 12 2024 Revised: Mar 16, 2024
Accepted: Mar 20, 2024 Published: Mar 30, 2024

Authors and Affiliation:

Salman Ahmed Mangrio^{1*}, Aijaz Ali²,
Murtaza Ahsan Ansari³, Muhammad Jamil
Memon⁴, Majid Bin Masood⁵, Tahir Hussain
Khan⁶

^{1,3} Dow international medical college DUHS,
Karachi, Pakistan

⁴Ziauddin Hospital Clifton, Karachi, Pakistan

⁵Medix Hospital Lahore, Pakistan

⁶Kulsumbai Valika Post Graduate Teaching
Hospital, SITE, Karachi, Pakistan

*Corresponding Author Email:
tahirhussainkhan99@gmail.com

Copyright & Licensing:



Authors retain copyright and grant the journal right of first publication with the work simultaneously licensed under a [Creative Commons Attribution \(CC-BY\) 4.0 License](https://creativecommons.org/licenses/by/4.0/) that allows others to share the work with an acknowledgment of the work's authorship and initial publication in this journal.

Conflict of Interest:

Author(s) declared no conflict of interest.

Acknowledgment:

No Funding received.

Citation: Mangrio SA, Ali A, Ansari MA, Memon MJ, Qureshi I, Masood MB, Khan TH. Grommet insertion in patients of secretory otitis media for improvement in Hearing. Medical Journal of South Punjab. 2024 March 30; 5(1):88-94.

Please scan me to access online.



An official publication of
Medteach Private Limited, Multan, Pakistan.
Email: farman@mjsp.com.pk, Website: <https://mjsp.com.pk/index.php/mjsp>



Grommet insertion in patients of secretory otitis media for improvement in Hearing

Salman Ahmed Mangrio^{1*}, Aijaz Ali², Murtaza Ahsan Ansari³, Muhammad Jamil Memon⁴, Majid Bin Masood⁵,
Tahir Hussain Khan⁶

^{1,3} Dow international medical college DUHS, Karachi, Pakistan

⁴Ziauddin Hospital Clifton, Karachi, Pakistan

⁵Medix Hospital Lahore, Pakistan

⁶Kulsumbai Valika Post Graduate Teaching Hospital, SITE, Karachi, Pakistan

*Corresponding Author Email: tahirhussainkhan99@gmail.com

ABSTRACT

Objective: to assess the improvement in hearing following grommet insertion in patients diagnosed with secretory otitis media.

Methods: A Quasi-Experimental study was conducted at Kulsumbai Valika Post Graduate Teaching Hospital, SITE, Karachi, Pakistan on 56 ears diagnosed with secretory otitis media from December 2022 to November 2023. Preoperative Pure Tone Audiometry (PTA) and tympanometry were performed to assess the patient's hearing status, with a significant hearing loss defined as 20-40 dB.. Postoperative PTA was repeated before discharge, focusing on the mean air conduction threshold at 500, 1000, and 2000 Hz.

Results: Preoperative hearing was mild (20-40 dB) in 25.0% ears, moderate (40-60 dB) in 37.5% ears and severe (60-80 dB) in 37.5% ears. Postoperative hearing loss was mild (20-40 dB) in 60.7% ears, moderate (40-60 dB) in 26.8% ears and severe (60-80dB) in 12.5% ears. The difference between preoperative hearing and postoperative hearing loss was statistically insignificant, ($p=0.285$).

Conclusion: Implantation of a grommet has been demonstrated to markedly enhance hearing in individuals diagnosed with secretory otitis media.

Keywords: Grommet insertion, Hearing loss, Infection, Middle ear effusion, Secretory otitis media,

1. INTRODUCTION

Hearing is widely regarded as humanity's most useful sense, as it facilitates effective communication, distinguishing humans from other animals¹. Reports indicate a significant global increase in hearing impairment, making it the most prevalent sensory defect in humans. Tonal audiometry remains the primary method for clinically evaluating hearing². Otitis media, a prevalent issue among teenagers, accounts for a substantial portion of visits to pediatric ENT specialists³.

Among children up to 90% population expected to develop secretory otitis media before the start of school life, making it a prevalent issue in childhood that is less common in adults⁴. Secretory otitis media (SOM), also known as OME fluid otitis media or "glue ear," is characterized by the presence of middle ear effusion (MEE) without evidence of acute infection⁵. This condition typically follows diagnosed or unrecognized acute otitis media (AOM) in children, although it can also occur alongside eustachian tube obstruction even in the absence of prior clinical infection^{6,7}.

Middle ear infections in young children can lead to undetected hearing loss, which may manifest as speech, language, behavioral, or educational difficulties⁸. However, myringotomy and grommet placement can swiftly improve hearing, enabling uninterrupted active learning and social integration with peers⁹.

SOM, diagnosed in 3.1% and 1.5% of first-grade students and second-grade students respectively, presents challenges due to increased incidence¹⁰, difficulty in diagnosis, prolonged duration, heightened risk of conductive hearing loss, potential impacts on language and cognition, and notable disparities in clinical practices, underscoring the importance of utilizing

current evidence-based guidance for effective management¹¹.

This study aims to address this gap in knowledge by systematically evaluating the efficacy of grommet insertion for improving hearing among patients diagnosed with SOM. This study seeks to provide clarity on the true efficacy of grommet insertion in improving hearing outcomes.

2. METHODOLOGY

A Quasi-Experimental study was conducted at Kulsumbai Valika Post Graduate Teaching Hospital, SITE, Karachi, Pakistan on 56 ears diagnosed with SOM from December 2022 to November 2023, employing a non-probability consecutive sampling technique for grommet insertion. Both sexes aged 5 and above, with clinical suspicion of SOM and presenting a type B tympanogram were included in the study. However, individuals with concomitant ear pathologies such as acute suppurative otitis media or a history of previous ear surgery were excluded from the analysis.

Permission was granted by the hospital's ethical committee prior to the grommet insertion surgery, and consent was obtained from the patient. A comprehensive examination of both ears was conducted, including microscopic examination of the tympanic membranes for any abnormalities. Preoperative Pure Tone Audiometry (PTA) and tympanometry were performed to assess the patient's hearing status, with a significant hearing loss defined as 20-40 dB. A grommet was inserted in the anterior inferior quadrant of the tympanic membrane under general anesthesia. PTA was repeated after surgery but before discharge, focusing on the mean air conduction threshold at 500, 1000, and 2000 Hz. A comparison between pre- and postoperative PTAs was made, analyzing changes in the air-bone gap at the specified frequencies, with all data meticulously recorded in a pre-designed questionnaire.

Collected data was analyzed by using SPSS version 27, mean and SD was calculated for numerical values and frequencies were calculated for categorical values. Only fisher exact test was applied to check the association of both variables of table 2. P-values less or equal to 0.05 were taken as significant.

3. RESULTS

Overall, 36 patients and 56 ears were included in this study with mean age 55.31 ± 10.51 years. There were 19 (52.8%) males and 17 (47.2%) females. Of the 56 ears, 36 (64.3%) were right ears, 14 (25.0%) were left and 6 (10.7%) were both ears. (Figure. I). (Table. I).

Preoperative hearing was mild (2040 dB) in 14 (25.0%) ears, moderate (4060 dB) in 21 (37.5%) ears and severe (6080 dB) in 21 (37.5%) ears. Whereas, postoperative hearing loss was mild (20-40 dB) in 34 (60.7%) ears, moderate (40-60 dB) in 15 (26.8%) ears and severe (60-80dB) in 7 (12.5%) ears. The difference between preoperative hearing and postoperative hearing loss was statistically insignificant, ($p=0.285$). (Table. II).

Table. I
Demographic characteristics and ears involvement of the study patients

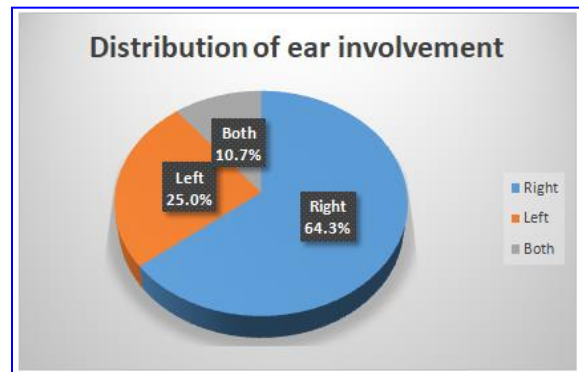
Characteristic	Presence
Age (years)	35.10±5.61
Gender	
Male	79 (60.8)
Female	51 (39.2)
Ears	
Right	36 (64.3)
Left	14 (25.0)
Both	6 (10.7)
Mean±S.D, N (%)	

Table. II
Association of preoperative hearing and postoperative hearing loss

	Postoperative hearing loss	p-value
--	----------------------------	---------

Preoperative hearing	Mild (20-40 dB) N=34	Moderate (40-60dB) N=15	Severe (60-80dB) N=7	
Mild 2040 dB N=14	8 (23.5)	3 (20.0)	3 (42.9)	0.285*
Moderate 4060 dB N=21	16 (47.1)	4 (26.7)	1 (14.2)	
Severe 6080 dB N=21	10 (29.4)	8 (53.3)	3 (42.9)	
N (%), column wise percentage, *insignificant				

Figure. I



4. DISCUSSION

In this study mean age of patient s was 55.31 ± 10.51 years and there were more males 52.8% than 47.2% females. In a study conducted by Zada et al¹² involving 28 patients diagnosed with SOM, a total of 48 ears were examined. Among these ears, 56.25% belonged to male patients, while 43.75% belonged to female patients. The age range varied from 7 to 55 years in patients, with a mean age of 14.10 ± 9.11 years.

William et al¹³ found that in five-year-olds, the annual prevalence of SOM was 17%, whereas in eight-year-olds, it was 6%. On the other hand, Hogan et al¹⁴ reported a prevalence of approximately 15% during the first three years of life, with a decreasing prevalence as children age. By the time children were screened in school at ages 8-13 years, only 1-5% were found to have SOM.

In this study preoperatively, 25.0% of ears exhibited mild hearing loss (20-40 dB), 37.5% had moderate loss (40-60

dB), and another 37.5% had severe loss (60-80 dB). Following surgery, 60.7% of ears experienced mild postoperative hearing loss, 26.8% had moderate loss, and 12.5% had severe loss. Aslam et al¹⁵ found that preoperative hearing loss was mainly moderate, but improved significantly post-grommet insertion, with most ears experiencing mild hearing loss afterward. Approximately a quarter of ears showed no improvement, while the majority saw a 5-10 dB improvement, and a smaller portion experienced a 10-20 dB improvement.

Over the past two decades, randomized clinical trials conducted by Butler et al¹⁶ and Rosenfeld et al¹⁷ have substantiated the efficacy of surgical treatment, specifically ventilation tubes (VTs), commonly referred to as grommets. The prevailing indication for surgery is the failure of conservative management for otitis media with effusion (OME) that persists beyond a duration of 3 months. While a myringotomy, involving an incision in the eardrum, typically closes spontaneously within 72 hours, the reversal of middle-ear pathophysiology necessitates time for resolution.

A study conducted by Marchisio et al¹⁸ and Folino et al¹⁹ has reported that Otitis Media with Effusion (OME) may lead to conductive hearing loss, which is believed to hinder language, speech, and cognitive development. Additionally, prospective cohort analyses have suggested that OME during early life may negatively impact later language development, although conflicting findings exist with some studies showing no such association.

The study conducted by Schilder et al²⁰ found that the placement of a grommet effectively maintains the opening of a myringotomy and prevents premature closure on a temporary basis.

In a study conducted by Zheng et al²¹, 80 cases were followed up for a period ranging from 6 to 12 months. Of the 144 ears

examined, 120 (83%) showed improvement in hearing and were considered cured. Additionally, tympanograms and pure-tone hearing thresholds were found to be normal in these cases.

The study follow-up period has not been long enough to assess the long-term efficacy of grommet insertion. Some improvements in hearing or other outcomes may be temporary, and longer follow-up periods are needed to evaluate sustained benefits.

Facilitate knowledge exchange and continuous learning through multidisciplinary case discussions and professional development activities among otolaryngologists.

5. CONCLUSION

Implantation of a grommet has been demonstrated to markedly enhance hearing in individuals diagnosed with secretory otitis media.

REFERENCES

1. Singh S, Kulkarni V. A Randomized Control Trial of Adenotonsillectomy with and without Insertion of Grommet in Treatment of Secretory Otitis Media. *Intern J Pharm Res* (09752366). 2020 Jan 1;12(1):1127.
2. Mudry A, Young JR. Otitis media with effusion: Politzer's 100 year legacy. *Intern J Pediatr Otorhinolaryngol*. 2020 Sep 1;136:110160.
3. Verma M, Shahakar R, Thorat R, Ghorpade C, Rangari P. Diagnostic assessment and various treatment modalities of secretory otitis media. *Intern J Surg*. 2020;4(1):209-14.
4. Rahman SA, Hossain D, Razzak MA, Alam MA. Hearing Improvement after Adenotonsillectomy with Myringotomy in Children with Otitis

- Media with Effusion. *J Brahmanbaria Med College*. 2022 Jan;4(1):12-5.
5. Abdel Tawab HM. Myringotomy with versus without grommet tube insertion in chronic serous otitis media with effusion: Southern Oman experience. *Egypt J Ear, Nose, Throat and Allied Sci*. 2020 Aug 1;21(2):82-7.
 6. Saleh AS, Sweed AH, Anany AM, Merwad EA. Assessment of Grommet Tube Insertion versus Myringotomy with Intratympanic Steroid Injection in Treatment of Otitis Media with Effusion. *The Egypt J Hospital Med*. 2023 Jan 1;90(1):1663-7.
 7. Mohammed H, Qureshi MH, Yates P. Outcomes of examination under anaesthesia of post-nasal space and grommet insertion in adults presenting with otitis media with effusion. *The J Laryngol & Otol*. 2021 Jul;135(7):620-4.
 8. Siyad AM, Venkataramanan R, Latheef MN. Secretory Otitis Media—A Clinical Prospective Study and its Management. *WWJMRD* 2021; 7(5): 107-110.
 9. Li L, Mao Y, Hu N, Yan W, Lu Y, Fan Z et al.. The effect of balloon dilatation eustachiantuboplasty combined with grommet insertion on the structure and function of the eustachian tube in patients with refractory otitis media with effusion. *Ann Palliative Med*. 2021 Jul;10(7):7662670-7670.
 10. Lei L, Wang D, Hao X, Ma X, Li Y, Zhao S, Zheng J, Han D. Therapeutic outcome and complication management of grommet insertion for radiotherapy induced otitis media with effusion. *Lin Chuang er bi yanhoutou Jing waikezazhi= J Clin Otorhinolaryngol, Head, and Neck Surg*. 2020 Apr 1;34(4):334-7.
 11. Yoo MH, Cho YS, Choi J, Choung YH, Chung JH, Chung JW et al. Factors Affecting the Extrusion Rate and Complications After Ventilation Tube Insertion: A Multicenter Registry Study on the Effectiveness of Ventilation Tube Insertion in Pediatric Patients With Chronic Otitis Media With Effusion—Part II. *Clin Experiment Otorhinolaryngol*. 2022 Nov;15(4):326.
 12. Zada B, Muhammad T, Habib M, Iqbal Z, Saleem R, Tayyab M. Efficacy of Grommet Insertion for Improvement in Hearing among Patients of Secretory Otitis Media. *PJMHS*. 2021;15(7):1857-59.
 13. Williamson JG, Dunleavy J, Robinson BA. A natural history of otitis Media with effusion. *J Laryngol&otol* 1994; 108: 930 -34.
 14. Hogon SC, Stratford KJ, Moore DR. Duration and recurrence of otitis media With effusion in children from birth to 3 year, prospective study using Monthlyotoscopy and tympanometry. *BMJ* 1997; 314-350.
 15. Aslam MJ, Jan A, Sharif A. Effect of Grommet Insertion on Hearing of Patients with Secretory Otitis Media. *PakJ Med& Health Sci*. 2013 Apr 1;7(2):407-10.
 16. Butler CC, Van Der Voort JH. Oral or topical nasal steroids for hearing loss associated with otitis media with effusion in children. *Cochrane Database Syst Rev* 2002; 4:CD001935.
 17. Rosenfeld RM, Post JC. Meta-analysis of antibiotics for the treatment of otitis media with effusion. *Otolaryngol Head Neck Surg*1992; 106: 378-386.

- 18.** Marchisio P, Bortone B, Ciarcia M, Motisi MA, Torretta S, Gattinara GC, Picca M, Di Mauro G, Bonino M, Mansi N, Varricchio A. Updated guidelines for the management of acute otitis media in children by the Italian Society of Pediatrics: Prevention. *The Pediatr Infect Dis Journal*. 2019 Dec 1;38(12S):S22-36.
- 19.** Folino F, Ruggiero L, Capaccio P, Coro I, Aliberti S, Drago L, Marchisio P, Torretta S. Upper Respiratory Tract Microbiome and Otitis Media Intertalk: Lessons from the Literature. *J Clin Med*. 2020 Sep;9(9):2845.
- 20.** Schilder AG. Assessment of complications of the condition and of the treatment of otitis media with effusion. *Int J Pediatr Otorhinolaryngol* 1999;49:247-51.
- 21.** Zheng Y, Xu L. [The therapy of children with secretory otitis media by myringotomy with grommet insertion and the relevant management]. *Lin Chuang Er Bi Yan Hou Ke Za Zhi*. 2001 Apr;15(4):155-6.